

CASE REPORT**Intestinal Duplication Cyst Mimicking as Mesenteric Cyst with Associated Ileal Atresia Type III A**

Surekha Arakeri ¹, Anilkumar Sirasagi ^{1*}

¹Department of Pathology, BLDEU's Sri B. M. Patil Medical College, Solapur Road, Bijapur - 586103 (Karnataka) India

Abstract:

Intestinal duplication cysts (IDC) are uncommon congenital malformations that could present diagnostic and therapeutic challenge. They may be often mistaken as mesenteric cysts, omental cyst, cystic lymphangioma etc. However, IDC are differentiated from other intra-abdominal cystic lesions by presence of gastrointestinal mucosal lining and smooth muscles in their wall. We report a case of IDC mimicking as mesenteric cyst associated with atresia of ileum in a neonate presented with acute surgical emergency.

Key words: Intestinal duplication cysts (IDC), mesenteric cyst, ileal atresia.

Introduction:

Intestinal duplication cysts (IDC) are uncommon congenital malformations first described by Fitz in 1844, but the entity IDC was coined by Ladd in 1937. These anomalies can occur anywhere from mouth to anus and have an incidence of 1 in 4500 [1, 2]. Etiology in IDC is not well established as intestinal duplication takes various forms. Various theories put forth to explain the embryologic basis for the duplications were defect in re-canalisation of intestinal lumen after solid stage of embryological development, partial twinning during embryogenesis, persistent embryological diverticula and split notochord theory [2, 3].

Case History:**Clinical presentation:**

A female neonate born after full term normal delivery, was presented with history of abdominal distension and 3-4 episodes of bilious vomiting on 2nd day. Baby had not passed meconium or stool. Mild distension of abdomen with visible intestinal peristalsis was noted on clinical examination. Abdominal radiography revealed multiple air- fluid levels.

The neonate was taken up for exploratory laparotomy which revealed ileal type IIIA atresia with a single cystic mass within the transverse mesocolon without sharing a common wall with transverse colon (Fig. 1).

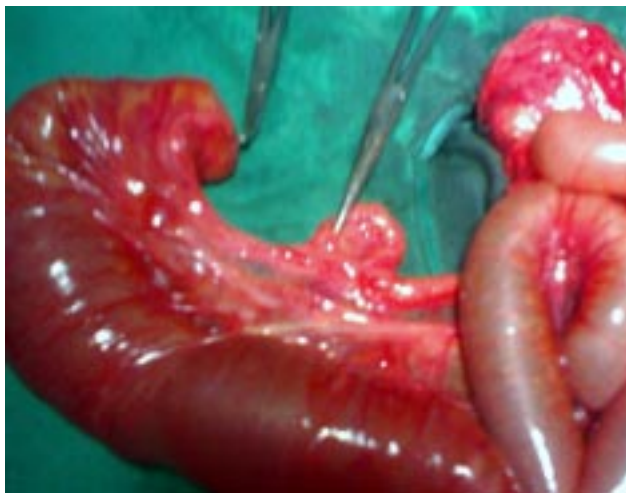

Fig. 1: Exploratory laparotomy photograph showing segment of small intestine and mesentery with a cystic mass

Based on these findings, a clinical diagnosis of mesenteric cyst and ileal atresia type IIIA was made. Ileoileal end to oblique anastomosis was done for ileal atresia with excision of mesenteric cyst.

Histopathological Findings:

Gross examination of excised mesenteric cyst revealed single cystic mass measuring 4x3x1cms with smooth external surface. On cutting it open, biloculated cyst filled with serous fluid was noted. A segment of small intestine measuring 2 cm having 0.5 cm cord like segment which was 1cm and 0.5 cm away from proximal and distal surgical margins was also received.

Microscopy of the mesenteric cyst showed fibro-collagenous cyst wall with focal lining of intestinal mucosa (Fig. 2)

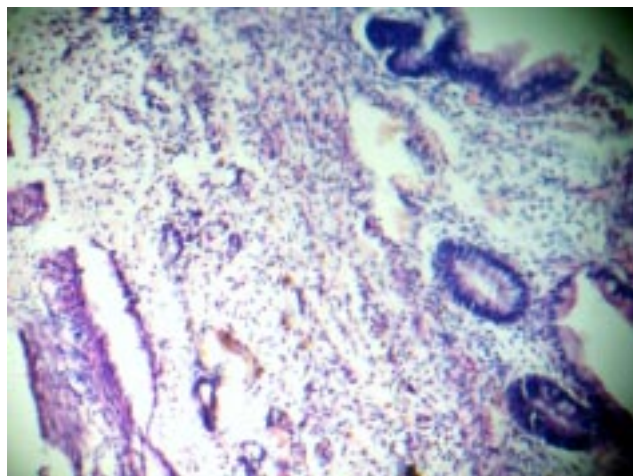


Fig. 2: Photomicrograph showing cyst wall with focal lining of intestinal mucosa (Hand E; X 100)

Cyst wall showed muscular layer, inflammatory cells, hemosiderin laden macrophages, cholesterol clefts and few multinucleated giant cells. Segment of small intestine showed features of atresia.

Discussion:

Gastrointestinal tract (GIT) duplication cysts are defined as cystic lesions located in or adjacent to the wall of part of GIT having smooth muscle in their wall and are lined by alimentary tract mucosa. They share a common wall and mesenteric blood supply with adjacent intestine but usually do not communicate with the lumen. Although adjacency to the GIT is part of the definition of these anomalies, cysts that fit other pathological criteria have been found in location that are relatively remote from alimentary tract such as tongue, pleural space, retroperitoneum etc [3, 4]. The non-communicating IDC which don't share a common wall with intestine can be mistaken as mesenteric cyst, omental cyst, cystic lymphangioma etc. However, mucosal lining and smooth muscle in cyst wall help to differentiate IDC from other cystic lesion [2, 3]. In our case, the cystic lesion is non-communicating and is not sharing a common wall with small intestine hence a clinical diagnosis of mesenteric cyst is made, but presence of mucosal lining and smooth muscle in cyst wall has helped to diagnose the lesion. IDC can be localized or associated with other anomalies such as esophageal atresia, diaphragmatic hernia, microcephaly, myelomeningocele, vertebral anomalies and cardiac anomalies [4, 5]. In our case IDC is associated with ileal atresia type III A.

Morbidity and mortality in these patients depends on severity and type of associated malformations. Symptoms and complications are also related to the location of duplication. Oral and esophageal lesions can create respiratory difficulties whereas lower gastrointestinal duplications may cause volvulus, intussusception,

obstruction and perforation [1, 5, 6]. In the present case, because of associated intestinal atresia, baby has presented with symptoms of obstruction. On post operative follow up, the baby is healthy.

Conclusion:

Although intestinal duplications are benign lesions, they may result in significant morbidity and mortality, if left untreated. Hence, early diagnosis and treatment is necessary. This case is presented as IDC are under reported and may present as cystic tumors, intussusceptions, perforation or gastrointestinal bleeding hence high index of suspicion is required in such cases.

References:

1. Puligandla PS, Nguyen LT, St-Vil D, Flageole H, Bensoussan AL, Nguyen VH, Laberge JM. Gastrointestinal duplications. *J Pediatr Surg* 2003; 38(5):740-744.
2. Michalsky M, Besner G. Alimentary tract duplications. *eMedicine Journal* 2002, 3:1-10.
3. Iyer CP, Mahour GH. Duplications of the alimentary tract in infants and children. *J Pediatr Surg* 1995; 30 (9):1267-1270.
4. Zahir I, Yusuf S, Zada F, Asif M, Akhtar N, M. Abbasi Z. Duplication Cyst in a New Born. *International Journal of Pathology* 2010; 8(2): 84-86
5. Macpherson RI. Gastrointestinal tract duplications: clinical, pathological, etiological and radiological considerations. *Radiographics* 1993; 13 (5):1063-1080.
6. Stern LE, Warner BW. Gastrointestinal duplications. *Semin Pediatr Surg* 2000; 9(3):135-140.

***Author for Correspondence:** Dr. Anilkumar Sirasagi, Assistant Professor, Department of Pathology, BLDEU's Shri. B. M. Patil Medical College Solapur Road, Bijapur - 586103 (Karnataka) India, Cell: 919164436611 Email: a_sirasagi@rediff.com, dranilss09@gmail.com